

Comparison of low-dose CT with CT/CT fluoroscopy guidance in percutaneous sacral and supra-acetabular cementoplasty

Veer Shah 

Travis Hillen 

Jack Jennings 

PURPOSE

Percutaneous cementoplasty is a minimally invasive treatment modality for painful osteoporotic and pathologic sacral and supra-acetabular iliac fractures. This study compares the use of low-dose CT guidance with CT/CT fluoroscopy in sacral and supra-acetabular cementoplasty.

METHODS

A retrospective review of patients who had undergone sacral or supra-acetabular cementoplasty was performed with patients grouped by use of CT/CT fluoroscopy or low-dose CT guidance during the procedure. Parameters evaluated included type of fracture, laterality of lesions, pain scores, pain medication use, imaging parameters, procedure time, dose-length product, effective dose, cement volume, and complications.

RESULTS

There were 17 patients identified who underwent cementoplasty utilizing dual CT/CT fluoroscopy, while 13 patients had their procedures performed with low-dose CT. There was a statistically significant decrease in radiation dose in the low-dose CT group (1481 mGy-cm) compared with the CT/CT fluoroscopy group (2809 mGy-cm) ($P = 0.013$). There was a significant decrease in procedure time with low-dose CT for bilateral lesions ($P = 0.016$). There was no significant difference between groups in complication rate ($P = 0.999$). Clinically nonsignificant cement extravasation occurred in two patients (10%) in the CT/CT fluoroscopy group and in one patient (8%) in the low-dose CT group ($P = 0.999$). There was a significant decrease in pain scores compared with baseline on the visual analogue scale in both groups at 1 week (low-dose CT $P = 0.002$, CT/CT fluoroscopy $P = 0.008$) and 1 month postprocedure (low-dose CT $P = 0.014$, CT/CT fluoroscopy $P = 0.004$), but no difference between groups at 1 day ($P = 0.196$), 1 week ($P = 0.368$), or 1 month ($P = 0.514$).

CONCLUSION

Sacral and supra-acetabular cementoplasties can be performed safely and precisely using low-dose multiple-acquisition CT guidance while providing significant radiation dose reduction with no difference in extravasation rates, postprocedural pain reduction, and complications compared with CT/CT fluoroscopy.

From the Department of Radiology (V.S. ✉ veer.shah@wustl.edu), Mallinckrodt Institute of Radiology, Washington University School of Medicine, St. Louis, Missouri, USA; Division of Musculoskeletal Radiology (T.H.), Department of Radiology (J.J.), Mallinckrodt Institute of Radiology, Washington University School of Medicine, St. Louis, Missouri, USA.

Received 24 July 2018; revision requested 24 August 2018; last revision received 03 January 2019; accepted 10 January 2019.

Published online 26 July 2019.

DOI 10.5152/dir.2019.18362

Percutaneous cementoplasty is a minimally invasive treatment modality for painful osteoporotic and pathologic sacral and supra-acetabular iliac fractures (1–3). The percutaneous treatment of sacral insufficiency fractures was first described by Garant (4) in 2002 and its use has become increasingly common. This procedure is primarily used to provide stabilization of fractures or lesions at risk of fracture with subsequent lessening or alleviation of pain, allowing patients to become mobile more quickly than medical therapy alone (5).

Frequently, percutaneous sacral and supra-acetabular cementoplasties are performed with CT, CT and standard fluoroscopy, or CT fluoroscopy for imaging guidance (6–8). CT provides better depiction of the osseous and neural anatomy, fracture characteristics including neuroforaminal or intra-articular extension, and near real-time guidance for needle placement within the lesion. In addition, in pathologic fractures, CT is used to define the extent of the underlying lesion, integrity of the osseous neuroforamina and supra-ac-

You may cite this article as: Shah V, Hillen T, Jennings J. Comparison of low-dose CT with CT/CT fluoroscopy guidance in percutaneous sacral and supra-acetabular cementoplasty. *Diagn Interv Radiol* 2019; 25:353–359.

etabular articular surface, all of which are associated with an increased likelihood of cement leakage and associated complications (9). While the use of CT and standard fluoroscopy is useful, this approach is typically not practical. Among other challenges, a portable C-arm fluoroscopy unit does not have adequate power to allow high quality imaging through the pelvis in many patients (10). CT fluoroscopy is therefore more widespread in use and permits real-time visualization of needle tracking and cement injection, reducing the risk of leakage (11). The limitations of CT fluoroscopy include a limited scanning range, inability to obtain orthogonal reconstructions, and an increased radiation dose to the operator compared with conventional CT-guided interventions (12–14). However, some studies have shown that CT-guided interventions increase the radiation dose to the patient, compared with CT fluoroscopy (15, 16).

At our institution, over the past two years, we have transitioned to the use of low-dose CT with serial imaging, without the use of CT fluoroscopy, in the percutaneous treatment of osteoporotic and pathologic sacral and supra-acetabular iliac fractures. This approach has the potential to decrease radiation dose to both patient and operator, while also decreasing procedure time. The objective of our study was to retrospectively compare the use of low-dose CT guidance alone to CT/CT fluoroscopy in percutaneous sacral and iliac cementoplasty, evaluating parameters that included procedure time, radiation dose including dose-length product and effective dose, procedural complications, and an assessment of pain scores.

Main points

- Sacral and supra-acetabular cementoplasty can be performed safely and precisely using low-dose CT guidance alone. Technical success was equal between groups. In particular, there was no difference in extravasation rates or complications during cement injection with sequential low-dose CT compared with CT/CT fluoroscopy.
- Serial imaging with low-dose CT provides a statistically significant radiation dose reduction to both patient and operator.
- Strategies to decrease CT dose include anatomy or attenuation-based tube-current modulation, noise-reduction algorithms, tube-voltage reductions in nonobese patients, and changing CT acquisitions from helical to axial.

Methods

This retrospective study was institutional review board approved and the need for informed consent was waived. Patients who received either dual CT/CT fluoroscopy or low dose CT percutaneous image-guided sacral and supra-acetabular cementoplasty procedures performed from 2014 to 2017 were identified from our institution's electronic medical record system and the musculoskeletal radiology department's procedure registry. Exclusion criteria included patients whose pelvic lesions were not supra-acetabular in location, or those who had concurrent thermal ablation performed during the procedure.

A chart review included patient demographics, body mass index (BMI), type of fracture (osteoporotic vs. malignant), type of cancer, numerical pain score, qualitative assessment of pain, and pain medication use. Baseline characteristics are displayed in Table 1. Procedural information including imaging used during procedure, imaging parameters, side/laterality of the procedure, procedure time, number of introducer needles, volume of cement, radiation dose length product (DLP) and effective dose was obtained. Postprocedural information included procedural complications, numerical and qualitative pain scores postprocedure, and pain medication use.

In the low-dose CT group, low-dose CT was acquired utilizing either the Siemens Somatom Sensation AS or the Siemens

Somatom Definition AS (Siemens Medical Systems). After a planning scan (reference parameters 100–120 kVp, automatic tube current modulation mAs 100–200, 3 mm contiguous slice thickness), the kVp and mAs were each manually adjusted to 100 and 80 respectively, for all patients. The z-axis length of the planning CT was at the discretion of the radiologist and depended on the sites of disease.

In the CT/CT fluoroscopy group, a planning CT scan (reference parameters: 100–120 kVp, automatic tube current modulation 100–200 mAs, 3 mm contiguous slice thickness) was obtained, followed by manual adjustment of the reference parameters to a “low-dose” CT protocol (manual adjustment to 100 kVp and 80 mAs respectively), as in the low-dose CT group, to allow for needle insertion. After these steps, in this group, real-time CT fluoroscopy was then acquired using the Siemens Somatom Definition AS with the CARE vision system (Siemens Medical Systems). Reference parameters were 120 kVp, 30 mAs, 6 mm contiguous slice thickness; 30 mAs was chosen as this technique best optimized visualization for the sacral neuroforamina and femoroacetabular joints to detect small amounts of early extravasation. No adjustments were made to the CT fluoroscopy (intraprocedural) parameters.

The patient was placed prone or supine on the CT table with conscious sedation utilizing intravenous midazolam and fentanyl. The needle insertion sites were prepared

Table 1. Baseline patient characteristics

	CT/CT fluoroscopy	Low-dose CT	P
Number of patients, n	17	13	
Age (years), mean±SD	69±9.94	66±12.34	0.378
Male, n (%)	4 (24)	4 (31)	0.999
BMI (kg/m ²), median (min–max)	25.7 (20.3–48.6)	26 (20–39.5)	0.376
Patients with sacral lesions, n			
Osteoporotic	8	4	
Pathologic	6	5	
Patients with supra-acetabular lesions, n			
Pathologic	4	4	
Patients with both sacral and supra-acetabular lesions, n			
Pathologic	2	0	

CT, computed tomography; SD, standard deviation; BMI, body mass index.

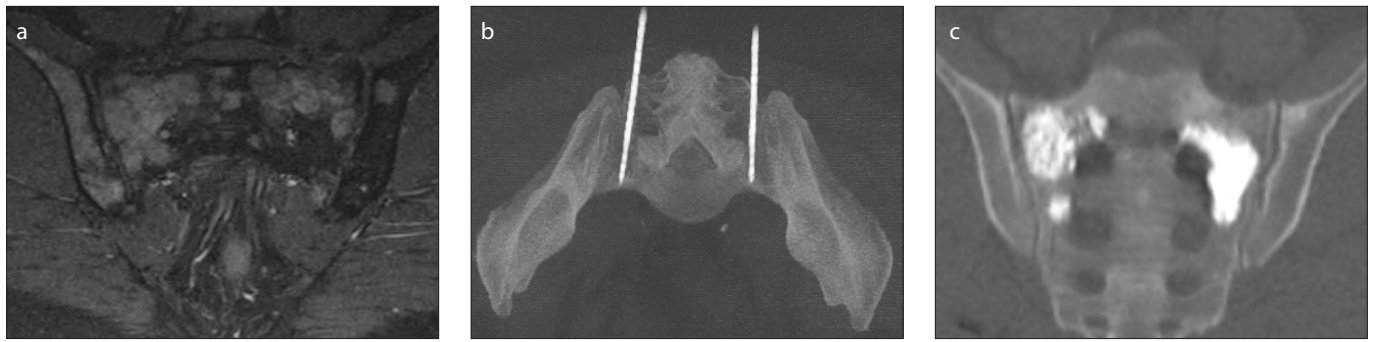


Figure 1. a–c. A 44-year-old woman with metastatic disease from breast cancer and painful sacral lesions at risk of pathologic fracture. Procedure performed with low-dose CT. Oblique coronal MRI fat-suppressed T1-weighted contrast-enhanced image (a) of the pelvis shows diffuse areas of marrow replacement and enhancement in the sacrum. Prone oblique transaxial maximum intensity projection (MIP), bone-windowed intraprocedural low-dose CT image (b) shows bilateral needles placed simultaneously along the long axis of the sacrum entering at S3 and extending to S1. Prone oblique coronal reformatted bone windowed low-dose CT image (c) following sacroplasty shows filling of the fractures bilaterally for stabilization. Note the lack of cement leakage into the sacral foramina.

with sterile technique, marked and local anesthetic administered. For dual CT/CT fluoroscopy, the needles were placed under low-dose CT guidance alone. A caudal to cranial oblique entry approach (i.e., entering at S3 and advancing to S1) was taken for the sacral fractures. An anterior to posterior approach was performed for the supra-acetabular cementoplasties with one or two needles at least 10 mm from the articular surface. Needle insertion was done using transaxial imaging; however, if needed, real-time orthogonal reformats were available during the procedure in the low-dose CT group and performed by CT technologist. Gantry tilt was not used, although it was available.

Once the needles were appropriately positioned, the polymethylmethacrylate (PMMA) was administered utilizing the Stabilit Vertebral Augmentation System (Merit/DFINE), using either low-dose CT or CT fluoroscopy guidance. Cement injection was performed while assessing for appropriate cement filling of the fracture/lesion and for cement extravasation into a sacral foramen, sacroiliac or hip joint. This was done using real-time monitoring in the CT fluoroscopy group and via sequential intermittent scans in the low-dose CT group. In the latter, the operator did not step out of the room and was positioned in a shielded area during the scan. If there was concern for impending extravasation or any actual extravasation identified, there was prompt termination of the cement filling and repositioning of the needle(s) once the cement had hardened.

Postprocedure images were performed with same reference parameters to demonstrate appropriate filling. Patients were

observed in the postprocedural recovery area for at least 90 minutes before being discharged home if performed as an outpatient procedure. Inpatients were returned to the inpatient care division approximately 30 minutes following the procedure. Clinical follow-up was performed either in person or via telephone at 1 day, 1 week, and 1 month. Procedure time was calculated by determining the time of acquisition of the first and last image of each procedure. Radiation dose was calculated by obtaining the DLP for each procedure, including the post-injection imaging. The DLP is the product of the volume CT dose index $CTDI_{vol}$ and scanning length (in centimeters) and serves as a measure of the total amount of radiation used during a given CT examination. An estimation of effective patient dose (mSv) was derived from the recorded DLP by means of a body-region specific conversion factor. The conversion factor (k) for the pelvis region was derived from the United Kingdom National Radiation Protection Board dataset, with a k-value of 0.015 (17).

In the low-dose CT group, two patients had CT-guided nerve root blocks performed after their cementoplasty, while in the CT/CT fluoroscopy group, one patient had a CT-guided hip injection and one patient had a lumbar epidural, also performed after successful cementoplasty. The additional radiation DLP for these procedures and extra procedure time was excluded from the final calculations. One patient in the low dose-CT group and two patients in the CT/CT fluoroscopy group had bone biopsies, while one patient in each group had CT-guided hip injections. For these patients, the needles were placed concurrently with the cementoplasty needles,

and therefore the DLP for these additional procedures were not excluded from the total.

Examples of sacral and supra-acetabular cementoplasty using low-dose CT are provided in Fig. 1 and using CT/CT fluoroscopy in Fig. 2.

Statistical analysis

Statistical analyses were performed with Stata (StataCorp 2011, Stata Statistical Software: Release 12). Data were analyzed using the Student *t* test when data were normally distributed and with the Mann-Whitney *U* test when the assumption of normality was not met. Dependent variables were analyzed using the Wilcoxon-signed rank test. For categorical variables, the Pearson's chi-square test was performed. *P* values less than 0.05 were considered statistically significant. Descriptive statistics are given as mean \pm standard deviation, median (min-max) and *n* (%).

Results

A total of 30 patients who had percutaneous sacral or supra-acetabular cementoplasty from January 2014 to December 2017 were identified (8 men, 22 women). There were 17 patients who had cementoplasty utilizing dual CT/CT fluoroscopy, including 3 patients who had an additional sacral or supra-acetabular cementoplasty for a second lesion, at a later time. There were 13 patients who underwent low-dose CT-guided sacral or iliac cementoplasty. The mean age of patients was 68 ± 11 years. There was no statistical difference in the median BMI of the patients in the low-dose CT group compared with the median BMI of patients in the CT/CT fluoroscopy group

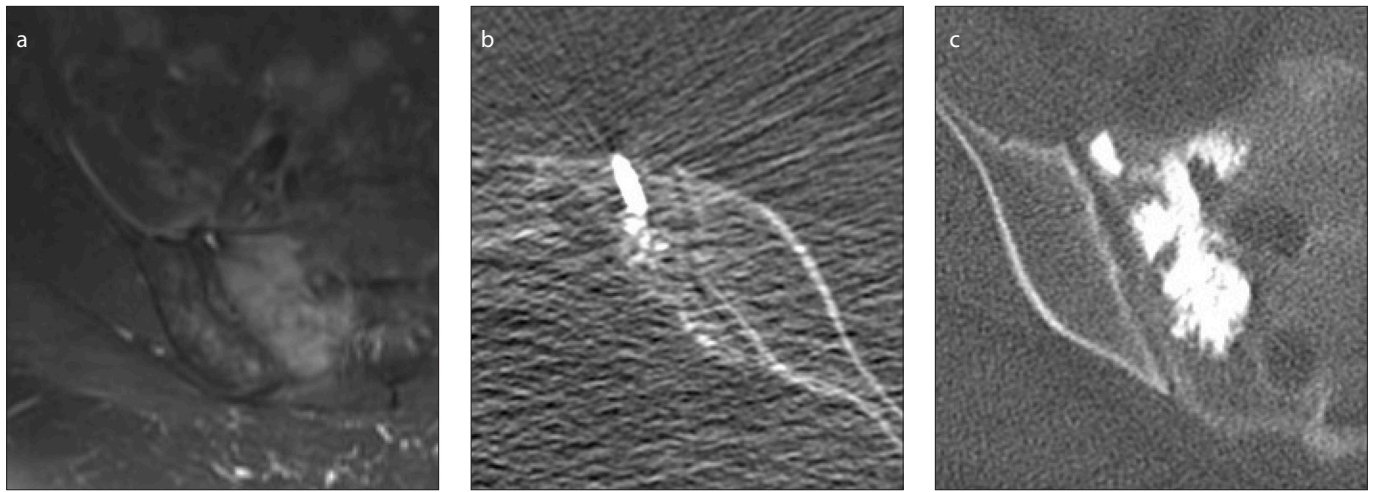


Figure 2. a–c. A 70-year-old woman with osseous metastatic disease from endometrial cancer and a large, painful right sacral insufficiency fracture. Procedure performed with CT/CT fluoroscopy. Oblique coronal fat-suppressed T1-weighted axial MRI (a) of the pelvis demonstrates the right sacral insufficiency fracture with surrounding edema. Intraoperative prone CT fluoroscopy (b) of the pelvis demonstrates needle within the right sacral lesion with real-time visualization of cement filling. Postprocedure oblique coronal bone-windowed CT (c) of the pelvis following cementoplasty demonstrates appropriate filling of the right sacral lesion for stabilization.

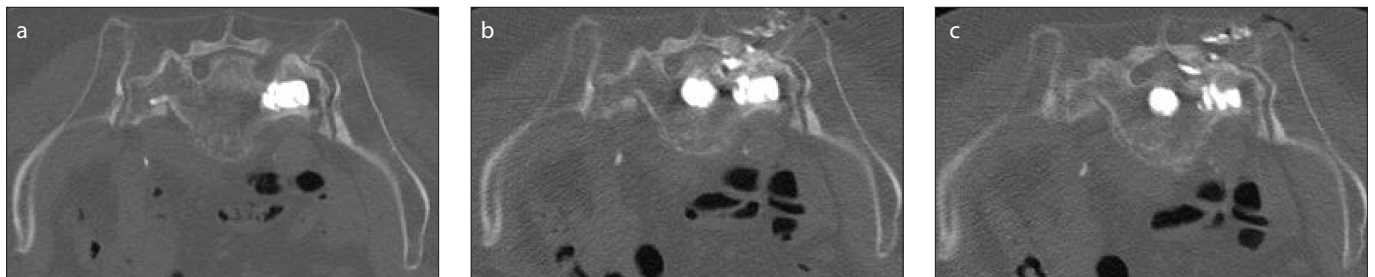


Figure 3. a–c. A 76-year-old woman with osteoporotic bilateral sacral insufficiency fractures and prior sacroplasty, now presenting for additional cementoplasty of new lesion. Procedure performed with low-dose CT. Prone bone-windowed intraprocedural low-dose CT images of the pelvis (a) show evidence of prior cementoplasty and a patent S1 neural foramen. Subsequent images at the end of the procedure show a small amount of cement in the right S1 neuroforamen (b). A 22-gauge needle was then placed and contrast instilled (c), which showed perineural contrast flow and confirmed a patent neuroforamen.

(26 kg/m² vs. 25.7 kg/m²; $P = 0.376$). Baseline characteristics are summarized in Table 1.

A total of 20 sacral or supra-acetabular/iliac cementoplasties were performed in 17 patients using CT/CT fluoroscopy and a total of 13 procedures were performed using low-dose CT technique in 13 patients. The former group included two patients who had both a sacroplasty and a supra-acetabular cementoplasty concurrently in the same procedure. In the CT/CT fluoroscopy group, a total of 8 bilateral and 8 unilateral sacroplasties were performed. In the low-dose CT group, a total of 8 bilateral and 1 unilateral sacroplasties were performed. The mean number of introducer needles used per procedure was 1.7. The mean volume of cement used per procedure was 15 mL. There was a statistically significant difference in the median cement volume used in the CT/CT fluoroscopy group compared with the low-dose CT group (8 mL vs. 18 mL; $P = 0.006$).

Technical success in terms of cement filling of the lesion was achieved in all procedures. Two cases (10%) in the CT/CT fluoroscopy group had non-clinically significant cement extravasation (<1 mL) identified into the S2 neural foramen and sacroiliac joint, compared with one case (8%) in the low dose CT group into the S1 neural foramen ($P = 0.999$) (Fig. 3). One patient in the CT/CT fluoroscopy group experienced postprocedural hip pain requiring local anesthetic and intra-articular steroid injection, although there was no cement extravasation identified on imaging. One patient in the low-dose CT group experienced intra-procedural hypertension and tachycardia requiring IV labetalol. Both patients' symptoms had resolved prior to discharge. There was no significant difference in procedural complications between the two groups ($P = 0.999$).

Mean procedure time was less in the low-dose CT group compared with the CT/CT

fluoroscopy group, although this was not statistically significant (74 min vs. 85 min; $P = 0.310$). When the laterality of lesions was compared between the two modalities, there was no difference in procedure times for unilateral lesions ($P = 0.5$), although procedure time for bilateral lesions was significantly less in the low-dose CT group ($P = 0.016$).

The median radiation DLP was also significantly lower in the low-dose CT group compared with the CT/CT fluoroscopy group (1180 mGy·cm vs. 2539 mGy·cm; $P = 0.003$). The median calculated effective patient dose was also statistically lower in the low-dose CT group compared with the CT/CT fluoroscopy group (17.7 mSv vs. 38.2 mSv; $P = 0.002$). Procedural details are summarized in Table 2.

The median patient reported preprocedural visual analogue scale (VAS) score was 8 in both CT and CT/CT fluoroscopy groups. Postprocedural VAS scores for the low-dose

CT group and the CT/CT fluoroscopy group at 1 day, 1 week and 1 month are given in Table 3. There was a statistically significant decrease in VAS scores compared with baseline at 1 week ($P = 0.008$) and 1 month ($P = 0.014$) in the low-dose CT group. There was also a statistically significant decrease in VAS pain scores in the CT/CT fluoroscopy group at 1 day ($P = 0.001$), 1 week ($P = 0.002$) and 1 month ($P = 0.004$). There was no difference in postprocedural pain reduction between the low-dose CT and CT/

CT fluoroscopy group at 1 day ($P = 0.143$), 1 week ($P = 0.510$), or 1 month ($P = 0.782$) (Table 4).

At 1 month, across both groups, 13 of 25 patients (52%) reported a decrease in analgesic use, 6 (24%) reported unchanged use, and 6 (24%) reported increased use compared with preprocedure pain medication use. However, there was no significant change in pain medication use at 1 month between the two groups ($P = 0.637$).

Discussion

Sacral and supra-acetabular cementoplasties present a unique set of challenges to the operator. The anatomical landmarks of the sacrum can often be difficult to appreciate in bone with underlying osteoporosis or tumor (6). In addition, the iliac bones of the pelvis prevent adequate visualization of the upper sacrum with lateral fluoroscopic evaluation. The pyramidal shape of the sacrum requires continuous multiple projections in order to localize instruments or implants within the sacrum (6). Supra-acetabular cementoplasties have the added risk of the sciatic nerve located posteriorly, necessitating an anterior approach and the risk of intra-articular leakage of contrast. CT has proven effective in providing better visualization of the anatomy, guidance for ease of needle placement, observing fractures with intraforaminal or intra-articular extension and evaluating for cement extravasation (18). In addition, the use of CT in obese patients may also facilitate the procedure and reduce the overall time required for cement installation (8).

Many modern CT scanners are now equipped with biopsy software packages that allow the acquisition and display of three or more slices in one rotation of the scanner. The newer shielded scanners also allow the radiologist to remain in the room while scanning without receiving the radiation dose, as is the current practice in our institution. By pressing the foot pedal in the room, the radiologist performing the intervention can immediately obtain a small number of contiguous slices, which allows verification of the needle position and correction of the position, if necessary (19).

The use of low-dose, multi-slice CT is becoming increasingly common in other areas of image-guided intervention, including lung biopsies, spinal injections, and abdominal drainage. However, there are still limited instances when continuous-mode

Table 2. Procedural details

	CT/ CT fluoroscopy	Low-dose CT	<i>P</i>
Total number of procedures, n	20	13	
Sacroplasty	14 (70)	9 (69)	
Supra-acetabular cementoplasty	4 (20)	4 (31)	
Concurrent sacral and supra-acetabular cementoplasty	2 (10)	0	
Procedure laterality			
Unilateral lesions	12 (60)	5 (38)	
Bilateral lesions	8 (40)	8 (62)	
Procedure time/min			
All lesions	82.5 (51–198)	66 (41–147)	0.113
Unilateral lesions	70.5 (51–198)	67 (47–121)	0.958
Bilateral lesions	89.5 (70–124)	64.5 (41–147)	0.016
Cement volume per procedure (mL)	8 (4–40)	18 (2–23)	0.006
Dose-length product (mGy-cm)	2539 (1227–7900)	1180 (633–3463)	0.003
Effective dose (mSv)	42.7 (18.41–118.5)	22.4 (9.75– 51.95)	0.002
Procedural complications			
Cement extravasation*	2 (10)	1 (8)	0.999
Other complication	1 (5)	1 (8)	0.999

Data are presented as n (%) or median (min–max).
CT, computed tomography.
*All cement extravasation cases were clinically nonsignificant.

Table 3. VAS scores for pain within groups

	Baseline VAS*	1 day VAS*	1 week VAS*	1 month VAS*	<i>P</i>		
					Baseline vs. 1 day	Baseline vs. 1 week	Baseline vs. 1 month
CT/CT fluoroscopy	8 (5–10)	5 (0–10)	5 (0–10)	5 (0–10)	0.001	0.002	0.004
Low-dose CT	8 (5–10)	6 (0–10)	5 (0–8)	5 (0–8)	0.092	0.008	0.014

VAS, visual analogue scale; CT, computed tomography.
*Data are presented as median (min–max).

Table 4. Comparison of VAS scores for pain between groups, relative to baseline

	Decrease in VAS scores compared with baseline		<i>P</i>
	CT/CT fluoroscopy	Low-dose CT	
1 day	-4.5 (-8 to 0)	-2.5 (-5 to 2)	0.143
1 week	-5 (-8 to 0)	-4 (-5 to -1)	0.510
1 month	-4.5 (-10 to 1)	-4 (-4 to -2)	0.782

Data are presented as median (min–max).
VAS, visual analogue scale; CT, computed tomography.

CT fluoroscopy may be appropriate, such as real-time placement of a needle into a small pulmonary nodule that is moving with respiration in patients with inconsistent breath-holds or experiencing difficulty in holding their breath or when a “very narrow” safe path is available for placing the interventional instruments, and critical structures need to be avoided and thus visualized in real time (20, 21).

It is generally agreed that radiation doses used in diagnostic and interventional procedures should be as low as reasonably achievable. When considering any interventional procedure, some authors have proposed that there is increased radiation to the patient with conventional CT (22), while others have shown that CT fluoroscopy increases radiation dose to the patient (19, 23). However, there is a paucity of studies in the literature that has evaluated the radiation dose in sacral intervention, and in particular, utilizing low-dose CT. In this study, we show that using low-dose CT can significantly reduce radiation dose to both the patient and the operator. In low-dose CT, only a definable single stack of images is obtained when the foot pedal is depressed. In contrast, in CT fluoroscopy, the patient is exposed to ionizing radiation as long as the radiologist is pressing the foot pedal. More commonly, procedures are performed using the “quick check technique” where the needle position is verified by a short CT fluoroscopy spot, which also results in a non-trivial radiation dose, although the dose is lower when compared with standard CT fluoroscopy (19).

There are a number of strategies available to reduce radiation dose in both modalities. In procedures utilizing CT fluoroscopy, the majority of the radiation dose is contributed by the planning CT scan rather than the procedure itself. Paik successfully showed that replacing the planning helical CT with a spot

CT fluoroscopy and adjusting subsequent patient positioning during scout and planning scans, was able to reduce the total radiation dose without compromising technical performance in cervical and lumbar transforaminal epidural injections (24, 25). However, it is important to note that replacing the preliminary helical CT with an in-room spot CT fluoroscopy may expose the operator to higher radiation doses (25) compared with a small field-of-view, low-dose CT scan.

Strategies to decrease radiation doses using CT have ranged from changing CT acquisitions from helical to axial, reducing tube current, and reducing nonessential imaging (21). If two percutaneous interventions are being performed in a single session, the planning image can be obtained at the level of both regions of interest and both percutaneous entry sites marked at the same time, eliminating the need for multiple planning images and reducing patient dose (26). This may explain our finding that procedure time was significantly less for bilateral lesions when performed using low-dose CT. Adding anatomy or attenuation-based tube-current modulation, noise-reduction algorithms, and/or tube-voltage reductions in nonobese patients may further reduce patient radiation doses, and these are strategies that have been successfully employed at our institution (27).

Artnet et al. used a multifaceted approach to decrease radiation exposure that included modifications to the parameters of the scout images, planning CT, and intraprocedural images (28, 29). In particular, patient selection for reduced radiation exposure protocol occurred on the basis of BMI. The relationship between increasing BMI and increased radiation dose is well established, with dose exposition increased by up to 96% in obese patients undergoing CT (30). In our study, there was no signifi-

cant difference between the BMI of patients in both groups.

In all procedures, cement was injected in small aliquots of 0.3–0.5 mL into the target for deposition. There was a significantly greater use of PMMA cement with low-dose CT guidance compared with CT/CT fluoroscopy. However, it is difficult to draw any meaningful conclusion from this fact, given the variability of lesion sizes and the greater proportion of bilateral cementoplasties in the low-dose CT group (62%) compared with the CT/CT fluoroscopy group (47%).

Overall technical success of the procedure in terms of safety and effectiveness, as evidenced by procedure completion of all attempted cases without significant complication and subsequent significant reduction in pain, is comparable to several large single-center cohort studies (31–33), although there is a paucity of large multicenter studies. In our study, the asymptomatic cement extravasation into the sacral neural foramina and sacroiliac joint were promptly identified, using either sequential low-dose CT scans or real-time CT fluoroscopy, and were similar between the two groups. While real-time visualization of cement injection/extravasation is a desirable benefit of CT fluoroscopy, there was no significant difference in the extravasation rates compared with CT guidance alone. In addition, in our experience, we have found that using sequential low-dose CT does not delay early identification of any extravasation, which is important in limiting severity of nerve injury, should this occur.

Both treatment groups had a significant reduction in pain. The number of patients who experienced decreased pain is slightly less than that reported by Bayley et al. (34), in which the patients reported 75%–100% relief of sacral pain and a significant decrease in opioid prescriptions. However, this may be a reflection of our small sample size and our inclusion of patients with pathologic fractures.

There are some limitations to this study. The current analysis is based on a small sample size and retrospective data from a single institution. Most of the procedures in this study were performed by a single operator with expertise in this field. It is likely that operator experience and complexity of the patient and planned intervention could impact on the multiple parameters assessed in this study. Comparing the results of two operators with similar experience but different techniques would have provided more

meaningful information; however, the data and patient numbers obtained were not adequate for this analysis. As neither patient size nor weight was recorded, image quality depending on different scanner settings was not evaluated.

In conclusion, the findings of this study demonstrate that sacral and supra-acetabular cementoplasties can be performed safely and precisely using low-dose multiple-acquisition CT guidance alone. A direct comparison of the two imaging modalities for a specific procedure (sacroplasty/supra-acetabular cementoplasty) showed that there was no difference in extravasation rates, postprocedural pain reduction and complications. The derived clinical implication is that serial imaging with low-dose CT provides statistically significant radiation dose reduction to both patient and operator and obviates the need for CT fluoroscopy in these procedures.

Conflict of interest disclosure

Veer Shah MBChB has no disclosures. Jack Jennings MD is a consultant for Bard Medical and Medtronic. Travis Hillen MD is a consultant for Medtronic.

References

1. Dasgupta B, Shah N, Brown H, Gordon TE, Tanqueray AB, Mellor JA. Sacral insufficiency fractures: an unsuspected cause of low back pain. *Br J Rheumatol* 1998; 37:789–793. [\[CrossRef\]](#)
2. Thomas EN, Cyteval C, Herisson C, Leonard L, Blotman F. Osteoporotic fracture of the sacrum: sacroplasty and physical medicine. *Ann Phys Rehabil Med* 2009; 52:427–435. [\[CrossRef\]](#)
3. Wallace AN, Tomasian A, Vaswani D, Vyhmeister R, Chang RO, Jennings JW. Radiographic local control of spinal metastases with percutaneous radiofrequency ablation and vertebral augmentation. *AJNR Am J Neuroradiol* 2016; 37:759–765. [\[CrossRef\]](#)
4. Garant M. Sacroplasty: a new treatment for sacral insufficiency fracture. *J Vasc Interv Radiol* 2002; 13:1265–1267. [\[CrossRef\]](#)
5. Butler CL, Given CA, 2nd, Michel SJ, Tibbs PA. Percutaneous sacroplasty for the treatment of sacral insufficiency fractures. *AJR Am J Roentgenol* 2005; 184:1956–1959. [\[CrossRef\]](#)
6. Kortman K, Ortiz O, Miller T, et al. Multicenter study to assess the efficacy and safety of sacroplasty in patients with osteoporotic sacral insufficiency fractures or pathologic sacral lesions. *J Neurointerv Surg* 2013; 5:461–466. [\[CrossRef\]](#)
7. Frey ME, DePalma MJ, Cifu DX, Bhagia SM, Daitch JS. Efficacy and safety of percutaneous sacroplasty for painful osteoporotic sacral insufficiency fractures: a prospective, multicenter trial. *Spine (Phila Pa 1976)* 2007; 32:1635–1640. [\[CrossRef\]](#)
8. Kamel EM, Binaghi S, Guntern D, Mouhsine E, Schnyder P, Theumann N. Outcome of long-axis percutaneous sacroplasty for the treatment of sacral insufficiency fractures. *Eur Radiol* 2009; 19:3002–3007. [\[CrossRef\]](#)
9. Katsanos K, Sabharwal T, Adam A. Percutaneous cementoplasty. *Semin Intervent Radiol* 2010; 27:137–147. [\[CrossRef\]](#)
10. Gupta AC, Yoo AJ, Stone J, et al. Percutaneous sacroplasty. *J Neurointerv Surg* 2012; 4:385–389. [\[CrossRef\]](#)
11. Cannavale A, Salvatori FM, Wilder A, Cirelli C, d'Adamo A, Fanelli F. Percutaneous vertebroplasty with the rotational fluoroscopy imaging technique. *Skeletal Radiol* 2014; 43:1529–1536. [\[CrossRef\]](#)
12. Nawfel RD, Judy PF, Silverman SG, Hooton S, Tuncali K, Adams DF. Patient and personnel exposure during CT fluoroscopy-guided interventional procedures. *Radiology* 2000; 216:180–184. [\[CrossRef\]](#)
13. Silverman SG, Tuncali K, Adams DF, Nawfel RD, Zou KH, Judy PF. CT fluoroscopy-guided abdominal interventions: techniques, results, and radiation exposure. *Radiology* 1999; 212:673–681. [\[CrossRef\]](#)
14. Kang SE, Lee JW, Kim JH, Park KW, Yeom JS, Kang HS. Percutaneous sacroplasty with the use of C-arm flat-panel detector CT: technical feasibility and clinical outcome. *Skeletal Radiol* 2011; 40:453–460. [\[CrossRef\]](#)
15. Bandela JR, Jacob RP, Arreola M, Griglock TM, Bova F, Yang M. Use of CT-based intraoperative spinal navigation: management of radiation exposure to operator, staff, and patients. *World Neurosurg* 2013; 79:390–394. [\[CrossRef\]](#)
16. Tabaraee E, Gibson AG, Karahalios DG, Potts EA, Mobasser JP, Burch S. Intraoperative cone beam-computed tomography with navigation (O-ARM) versus conventional fluoroscopy (C-ARM): a cadaveric study comparing accuracy, efficiency, and safety for spinal instrumentation. *Spine (Phila Pa 1976)* 2013; 38:1953–1958. [\[CrossRef\]](#)
17. Shrimpton PC HM, Lewis MA, Dunn M. Doses from computed tomography (CT) examinations in the UK-2003 review. Chilton, UK: National Radiological Protection Board; 2005.
18. Gangi A, Kastler BA, Dietemann JL. Percutaneous vertebroplasty guided by a combination of CT and fluoroscopy. *AJNR Am J Neuroradiol* 1994; 15:83–86.
19. Prosch H, Stadler A, Schilling M, et al. CT fluoroscopy-guided vs. multislice CT biopsy mode-guided lung biopsies: accuracy, complications and radiation dose. *Eur J Radiol* 2012; 81:1029–1033. [\[CrossRef\]](#)
20. Paulson EK, Sheafor DH, Enterline DS, McAdams HP, Yoshizumi TT. CT fluoroscopy-guided interventional procedures: techniques and radiation dose to radiologists. *Radiology* 2001; 220:161–167. [\[CrossRef\]](#)
21. Lamba R. Radiation dose optimization for CT-guided interventional procedures in the abdomen and pelvis. *J Am Coll Radiol* 2014; 11:279–284. [\[CrossRef\]](#)
22. Carlson SK, Bender CE, Classic KL, et al. Benefits and safety of CT fluoroscopy in interventional radiologic procedures. *Radiology* 2001; 219:515–520. [\[CrossRef\]](#)
23. Kloeckner R, dos Santos DP, Schneider J, Kara L, Dueber C, Pitton MB. Radiation exposure in CT-guided interventions. *Eur J Radiol* 2013; 82:2253–2257. [\[CrossRef\]](#)
24. Paik NC. Radiation dose reduction in CT fluoroscopy-guided cervical transforaminal epidural steroid injection by modifying scout and planning steps. *Cardiovasc Intervent Radiol* 2016; 39:591–599. [\[CrossRef\]](#)
25. Paik NC. Radiation dose reduction in CT fluoroscopy-guided lumbar interlaminar epidural steroid injection by minimizing preliminary planning imaging. *Eur Radiol* 2014; 24:2109–2117. [\[CrossRef\]](#)
26. Sarti M, Brehmer WP, Gay SB. Low-dose techniques in CT-guided interventions. *Radiographics* 2012; 32:1109–1120. [\[CrossRef\]](#)
27. Shepherd TM, Hess CP, Chin CT, Gould R, Dillon WP. Reducing patient radiation dose during CT-guided procedures: demonstration in spinal injections for pain. *AJNR Am J Neuroradiol* 2011; 32:1776–1782. [\[CrossRef\]](#)
28. Artner J, Cakir B, Weckbach S, Reichel H, Lattig F. Radiation dose reduction in CT-guided periradicular injections in lumbar spine: Feasibility of a new institutional protocol for improved patient safety. *Patient Saf Surg* 2012; 6:19. [\[CrossRef\]](#)
29. Artner J, Lattig F, Reichel H, Cakir B. Effective radiation dose reduction in computed tomography-guided spinal injections: a prospective, comparative study with technical considerations. *Orthop Rev (Pavia)* 2012; 4:e24. [\[CrossRef\]](#)
30. Boos J, Lanzman RS, Meineke A, et al. Dose monitoring using the DICOM structured report: assessment of the relationship between cumulative radiation exposure and BMI in abdominal CT. *Clin Radiol* 2015; 70:176–182. [\[CrossRef\]](#)
31. Gupta AC, Chandra RV, Yoo AJ, et al. Safety and effectiveness of sacroplasty: a large single-center experience. *AJNR Am J Neuroradiol* 2014; 35:2202–2206. [\[CrossRef\]](#)
32. Moussazadeh N, Laufer I, Werner T, et al. Sacroplasty for cancer-associated insufficiency fractures. *Neurosurgery* 2015; 76:446–450. [\[CrossRef\]](#)
33. Frey ME, Warner C, Thomas SM, et al. Sacroplasty: a ten-year analysis of prospective patients treated with percutaneous sacroplasty: literature review and technical considerations. *Pain Physician* 2017; 20:E1063–1072.
34. Bayley E, Srinivas S, Boszczyk BM. Clinical outcomes of sacroplasty in sacral insufficiency fractures: a review of the literature. *Eur Spine J* 2009; 18:1266–1271. [\[CrossRef\]](#)